THE IMPORTANCE OF FLEXION IN VACUUM EXTRACTOR DELIVERY

Published in The British Journal of Obstetrics and Gynaecology
March 1976. Vol 83. pp 194-200

Author
G. C. BIRD
Senior Obstetrician and Gynaecologist, Department of Public Health
Papua New Guinea

Abstract of relevant discussion points

1) A study of two large series of vacuum extractor operations suggested that failed vacuum extractor rates can be reduced by using cups that are more manoeuvreable and which accept stronger oblique traction than Malmström's cup.

2) Application of axis traction to a vacuum extractor cup maintains or promotes complete flexion and synclitism of the fetal head if the centre of the cup is on, or directly behind, the posterior end of the mento-vertical diameter, but deflexion (less than complete flexion) if it is in front of this point. Rydberg (1954) has shown that the fetal head is completely flexed when its mento-vertical diameter points in the direction of descent and that the posterior end of this diameter is 3 cm in front of the posterior fontanelle in the average case.

3) Designed to study an important but apparently little-appreciated aspect of vacuum extractor delivery: the relationship between the position of the cup and the position of the occiput at application of the cup and, in posterior and lateral positions, at delivery

4) If it is accepted that completely flexing applications are centred on or behind the posterior end of the mento-vertical diameter, completely flexing application distances vary according to the size of the head, the amount of moulding and the diameter of the cup.

5) The use of cups that are more manoeuvreable than Malmström's should, by permitting better applications, decrease failure rates, particularly when the occiput is obliquely posterior or lateral.

6) Consistently good results with the vacuum extractor require consistently good applications.

7) Consistently good applications demand accurate diagnosis of the position of the occiput and the direction of the sagittal suture, knowledge of the ideal application site, and a manoeuvreable cup.

8) Because the ideally applied cup does not always point in the direction of the pelvic axis, the initial pull sometimes has to be oblique. The cup must not become easily detached when subjected to this type of traction.

9) After application and before induction of the operating vacuum, the position of the cup should be carefully checked. If the distance between its anterior edge and the posterior angle of the bregma is less than 3 cm, or if the sagittal suture does not point to the centre of the cup, the cup should be removed (unless the head is at the outlet) and reapplied. Moving it back by as little as 1 cm may prevent failure and other complications.
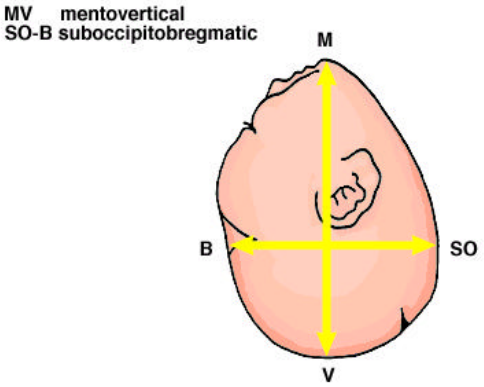
10) Difficult vacuum extractions, scalp and deeper trauma, failure to extract and subsequent Caesarean section (or symphysiotomy) for disproportion are sometimes the result of promoting or failing to correct deflexion.